



Case Presentation #1

Autism & Persistent Developmental Delay (PDD)

- 7 year old male who is repeating kindergarten.
 - * Born one week overdue and a difficult labor, becoming “stuck” in the birth canal and requiring forceps extraction.
 - * Global developmental delay. Patient on Ritalin and Prozac.
- Main problems included poor enunciation, limited vocabulary, short, nearly unintelligible sentences, no coordination, 2 year cognitive delay, attention deficit, emotional outbursts, autistic behavior, and drooling.
- Scan 1: Baseline scan shows decreased flow, to the frontal lobes and both temporal lobes, especially the left.
- Scan 2: 1 HBOT treatment shows recoverable tissue & improvement to both temporal lobes.
- Patient received 40 HBOTs and weaned from Ritalin and Prozac.
 - * Drooling gone, speech and cognition improved.
 - * Dad stated that the attention deficit was “1000% improved and emotional outbursts and autistic tendencies 100,000%” improved.
- Patient received another 25 HBOT treatments over the next year and continued to globally improve. He now speaks in full sentences and very active in sports for the first time in his life.
 - * He continues to be medication free.

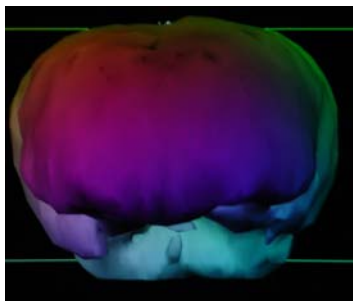
May 6, 2004 Government Oversight Committee
Copyright Retained
Paul G. Harch, M.D. 2004



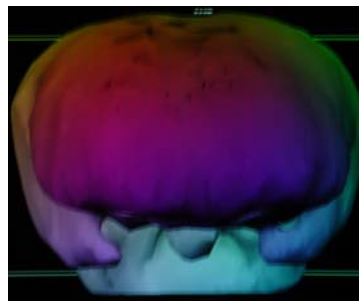
Case Presentation #1

Autism & Persistent Developmental Delay (PDD)

7 y. male



Baseline



1 HBOT

Diagnostic showing
recoverable brain tissue

May 6, 2004 Government Oversight Committee
Copyright Retained
Paul G. Harch, M.D. 2004



Case Presentation #2

Autism

- Two ½ year old girl, C-section birth, to mother whose pregnancy was complicated by freon exposure x 2, asthma, bronchitis, nausea, vomiting, dehydration with hospital admission in third trimester.
 - * Child had severe reflux with minimal weight gain first two months.
 - * Abnormal social interaction and laugh at 3 months.
 - * MRI normal, abnormal EEG
- Problems: No communication, minimal emotional development, dd/inappropriate behavior, hypotonia
- First SPECT: Bilateral temporal and frontal lobe abnormalities
- SPECT after 1 HBOT and course of HBOT: Improved
- HBOT: Three month course
 - * Improved: Self feeding, eye contact, tone, attention/interaction; increased activity, appetite and weight gain, stopped biting people, calmer. Very loving, improved relationship with 6 year old sister that improved sister's emotional disturbance caused by the patient's autism—beneficial effect on entire family.

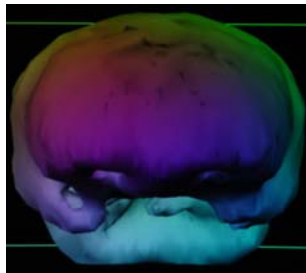
May 6, 2004 Government Oversight Committee
Copyright Retained
Paul G. Harch, M.D. 2004



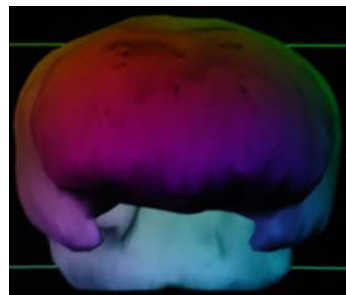
Case Presentation #2

Autism

2 ½ y. female

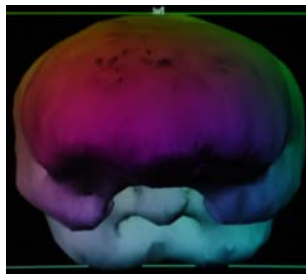


Baseline



1 HBOT

Diagnostic showing
recoverable brain tissue



40 HBOT

May 6, 2004 Government Oversight Committee
Copyright Retained
Paul G. Harch, M.D. 2004



Case Presentation #3

Autism

- Eight year old girl. Normal pregnancy and delivery.
 - * Bottle-fed, aspiration in hospital with cyanosis. Resuscitation without intubation.
 - * Hospitalized for 5 days.
- 4 months old: Incoordination, poor eye movement, blank stare, delayed motor.
 - * Extensive evaluation for two years
- Problems: Minimal speech, limited understanding, global motor delay, abnormal gait, inability to sleep, autistic behaviors.
 - * MRI: microcephaly.
 - * Underwent multiple treatments, including secretin, ongoing chelation
- First SPECT: Abnormal temporal and frontal lobes, especially left side
- SPECT after 1 HBOT and course of HBOT: Improved
- HBOT: Three blocks of treatment over two years.
 - * Improved attention span, vocabulary, communication, understanding, behavior, calmer, follows commands. Previously needed four sleeping pills at night, now one and sleeps most of the night.

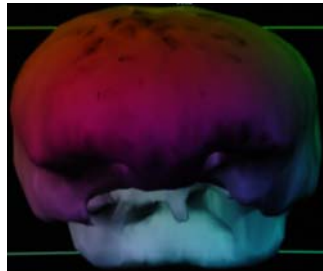
May 6, 2004 Government Oversight Committee
Copyright Retained
Paul G. Harch, M.D. 2004



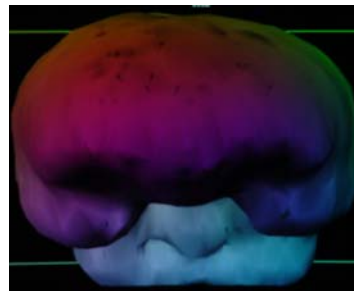
Case Presentation #3

Autism

8 y. female

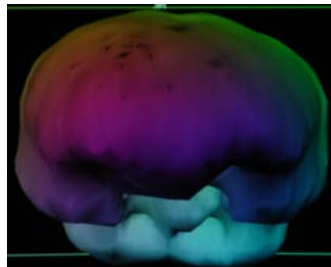


Baseline



1 HBOT

Diagnostic showing
recoverable brain tissue



40 HBOT

May 6, 2004 Government Oversight Committee
Copyright Retained
Paul G. Harch, M.D. 2004